

## Use Of Diode Laser In The Management Of Oral Leukoplakia – A Study Of 10 Cases.

Vatsal Ramwala

Career Postgraduate, Department of Oral and Maxillofacial Surgery, Karnavati School of Dentistry, 907/A, Uvarsad, Gandhinagar, Gujarat, India.

---

### **Abstract**

#### **Objective:**

To study the use of diode laser in the management of oral leukoplakia

#### **Methods:**

10 systemically healthy patients were selected having oral leukoplakia which is confirmed by punch biopsy, treated with diode laser and bleeding, pain, healing, recurrence were observed.

#### **Results:**

Very good healing at the end of 7th postop day and 30<sup>th</sup> postop day with less bleeding and pain and no recurrence in 1 year follow up

#### **Conclusion:**

Diode laser ablation is an effective treatment option in the management of oral leukoplakia

#### **Practice implication:**

Diode laser in small and compact, easy to use and cost effective unit compared to other laser units. Treating leukoplakia with diode laser prevents malignancy.

**Keywords:** Biopsy, Leukoplakia, Laser

---

### I. Introduction

Schwimmer in 1877 first coined the term 'leukoplakia'. The name derives from Greek and is a combination of two words: 'Leokos' means white and 'Plakos' means patch.<sup>1</sup> Various definitions have evolved with time for leukoplakia. World Health Organisation in 2005 defined it as "a white plaque of questionable risk having excluded known diseases or disorders that carry no increased risk for cancer".<sup>2</sup>

The etiology of leukoplakia is considered multifactorial, but smoking is appreciated to be a frequently involved factor.<sup>3</sup> Clinically it is classified as early or thin, homogenous or thick, verruciform and speckled or erythroleukoplakia. Speckled type has highest risk of malignancy.<sup>4</sup> Nonsurgical treatment modalities include vitamins, antioxidants, bleomycin and photodynamic therapy, whereas surgical treatments are excision with grafting, LASER ablation and cryosurgery.<sup>5</sup>

Diode is a semiconductor type laser with optical fibre delivery system. Its wavelengths are near infrared: 635, 670, 810, 830 and 980 nm. It is considered as class III lasers where direct viewing is hazardous to eyes. Two key features of soft tissue laser procedure are reduced bleeding intraoperatively and less pain postoperatively compared to conventional techniques.<sup>6</sup>

### II. Materials and Methods

The study was approved by institutional ethical committee and Informed consents were obtained from all the cases participated in the study. The Ten systemically healthy patients were selected with clinical diagnosis of leukoplakia of buccal mucosa and labial mucosa (Table 1). Routine haematological investigations were done. Clinical diagnosis was confirmed with the help of punch biopsy, where the small punch of tissue was sent for microscopic examination.

Diode laser unit having wavelength of 810/980 nm, input voltage DC 26V/4A at 4 Watts and fibre core diameter  $\geq 200$  micrometer was used (Fig. 1). Laser ablation of leukoplakia was planned under local anaesthesia. All the cases were operated by the same surgeon. All universal precautions were followed (Fig. 2). Laser beam was used in continuous mode and direct contact mode with tissue to be ablated. In paint brush manner with light hands, lesion was gradually ablated from mucosa by thermal energy of laser beam. Gauze pieces wetted with normal saline were used to keep wiping out the ablated tissue (Fig. 3, 6 & 7). Fume released from vaporization of epithelium was continuously removed by air evacuator. Clear surgical field was easily maintained by the least bleeding. Wound was allowed to heal secondarily. Healing was followed up on 7<sup>th</sup> and 30<sup>th</sup> postoperative days (Fig. 4 & 5) Intraop bleeding was also examined. Postoperative pain was measured on the basis of visual analogue scale.

### **III. Results**

Healing was indexed according to healing index by Landry<sup>7</sup>. Overall healing was good to very good on 7<sup>th</sup> day and Excellent on 30<sup>th</sup> day in all the cases (Table 2). Visual analogue scale was low in all the cases indicating the less pain or no pain post operatively on 3<sup>rd</sup> day (Table 3). Pain disappeared in all the cases on 7<sup>th</sup> postop day. All the patients are under follow up since a year and no recurrence has been found. Patients have also discontinued their tobacco consumption habits after treatment.

### **IV. Discussion**

The aim of treating the leukoplakia is to prevent malignant transformation and early diagnosis of malignancy for timely intervention. The major problem that the clinician has to face in the management of leukoplakia is the lesion is mostly asymptomatic.<sup>8</sup> In the evaluation of the patient, leukoplakia is a clinical diagnosis of exclusion.<sup>9</sup>

Diode laser can be utilised effectively in the management of leukoplakia. It is small, compact and easy to use laser unit. Diode is a semiconductor type laser containing gallium-aluminium-arsenide as an active medium. Based on photothermal effect, diode laser can either excise or can ablate/vaporize the tissue. In our study we have done ablation of Leukoplakia. The diode laser causes more thermal damage zone and marginal damage of biopsy species making histopathological examination difficult.<sup>10</sup> So in our study we did small punch biopsy preoperatively to confirm the clinical diagnosis of leukoplakia.

The advantages of diode laser application are relatively bloodless surgery, minimal swelling, scarring and coagulation, no need for suturing, reduction in surgical time, less or no post surgical pain and the laser disinfects the wound instantly.<sup>10</sup> In our study we observed almost bloodless field and minimal or no postoperative pain in all the cases.

Diode laser transmits energy to the cells causing warming, welding, coagulation, protein denaturation, drying, vaporization and carbonization. Laser induced wounds because of definite and clean wound generally heal with secondary intention and no scar formation, this is may be due to minimal degree of wound contraction.<sup>10</sup> In our study, in all the cases healing was by secondary intention and the healing progress was very good from the day of surgery to 7<sup>th</sup> day to 30<sup>th</sup> day.

Ishii J et al in their study of laser surgery as a treatment for oral leukoplakia found the recurrence in 29.3% of cases.<sup>11</sup> In our study during the period of 1 year follow up till now we have not found any case of recurrence.

The diode and Nd:YAG lasers are alike in that these lasers are absorbed in pigmented tissues and wavelengths are transmitted to their targets in contact with fibre.<sup>12</sup> The disadvantage of this fibre tip is 'hot tip effect'; the black denatured tissue protein clings to the fibre tip and heavily absorbs the laser energy, thus heating the tip to several hundred degrees. When this tip touches the tissue, the heat causes thermo mechanical tissue cutting and coagulation. But this black deposit is continuously scrapped away as the fibre passes over tissue leading to fluctuation in cutting and coagulation power.<sup>13</sup>

Recent advance in diode laser system is "Thermo Optically Powered (TOP)" surgery. In this system computer controlled semiconductor laser is used as power source and its power is converted into thermo optical power. This mechanism converts monochromatic laser light into thermal power and polychromatic with wavelengths in the range of 1,400 nm to 11,000 nm. This is near to the wavelength of CO<sub>2</sub>. The overall effect is enhancing effect on the cutting and cauterizing power.<sup>13</sup>

The significant hazards of laser energy are laser skin burns, eye damage and even blindness to operator, patient and supporting staff. It requires additional training to surgeon and supporting staff. Continuous maintenance of equipment is necessary. These aspects should be given enough consideration while using the laser system.<sup>14</sup>

### **V. Conclusion**

The diode laser system is easy to use, compact and small unit compared to other laser units. It is also cost effective for the patients. It gives good results after ablation of oral leukoplakia with relatively bloodless field, less pain and overall good patient compliance. Thus its use to treat oral leukoplakia and to prevent the malignancy becomes promising while keeping in mind basic laser operative precautions.

### **Conflict of interest**

Potential Conflict Of Interest Relevant To This Article Does Not Exist.

### **References**

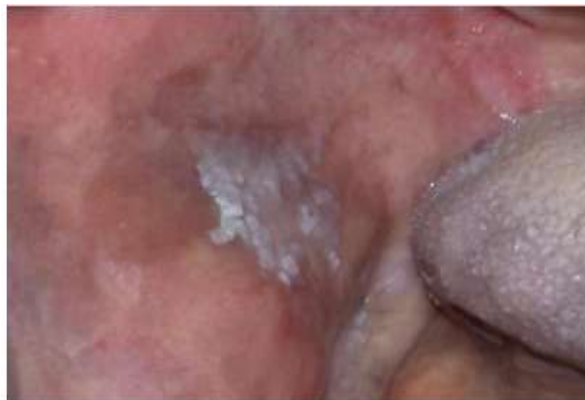- [1]. Anna Starzynska, Anita Pawlowska, Dorota Renkielska et al. Estimation of oral leukoplakia treatment records in the research of the department of maxillofacial and oral surgery, medical university of Gdansk. *Postep Derm Alergol* 2015; xxxII, 2: 114-122.
- [2]. Mohammed Abidullah, G Kiran, Kavitha Gaddikeri et al. Leukoplakia – Review of a potentially malignant disorder. *J Clin Diagn Res.* 2014 Aug;8(8):ZE01-4.

- [3]. Ioanina Parlatescu, Carmen Gheorghe, Elena Coculescu et al. Oral leukoplakia – an update. J Clin Med 2014; Vol. 9: No. 1.
- [4]. K. M. K. Masthan, N. Aravindha Babu, S. Leena Sankari et al. Leukoplakia: A short review on malignant potential. J Pharmacy and Bioallied Sciences April 2015; Vol 7: Supplement 1.
- [5]. Anand Kumar, Luke Cascarini, James A. McCaul et al. How should we manage oral leukoplakia ? Br J Oral Maxillofac Surg. 2013 Jul;51(5):377-83.
- [6]. LJ Walsh. The current status of laser application in dentistry. Australian Dental Journal 2003;48(3):146-155.
- [7]. Landry RG, Tumbell RS. Effectiveness of benzydamine HCL in treatment of periodontal post surgical patients. Res. Clin Forums 1988;10:105-118.
- [8]. Giovanni Lodi, Andrea Sardella, Cristina Bez et al. Systemic review of randomized trials for the treatment of oral leukoplakia. J of Dental Education 2002 Aug; Vol 66: No 8.
- [9]. Neville BW. Oral cancer and precancerous lesions. CA Cancer J Clin. 2002 Jul-Aug;52(4):192-215.
- [10]. Ehsan Azma, Nassimeh Safavi. Diode laser application in soft tissue oral surgery. J. Lasers in medical sciences 2013;Vol. 4: Number 4.
- [11]. Ishii J et al. Laser surgery as a treatment for oral leukoplakia. Oral Oncol 2003 Dec;39(8):759-69.
- [12]. Mitchell A. Lomke. Clinical applications of dental lasers. Gen. Dent. 2009 Jan-Feb.
- [13]. Romanos GE. Diode laser soft-tissue surgery: Advancements aimed at consistent cutting, improved clinical outcomes. Compend Contin Educ Dent. 2013 Nov Dec;34(10):752-7.
- [14]. Aruna Tambuwala, Amit Sangle, Akram Khan et al. Excision of oral leukoplakia by CO<sub>2</sub> laser versus traditional scalpel: A Comparative study. J Maxillofac Oral Surg. 2014 Sep;13(3):320-7.

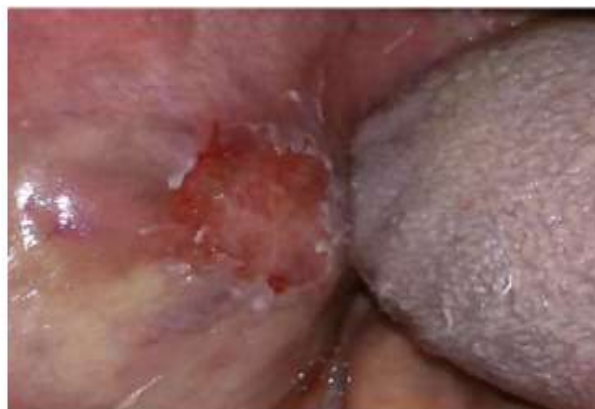**Figures**



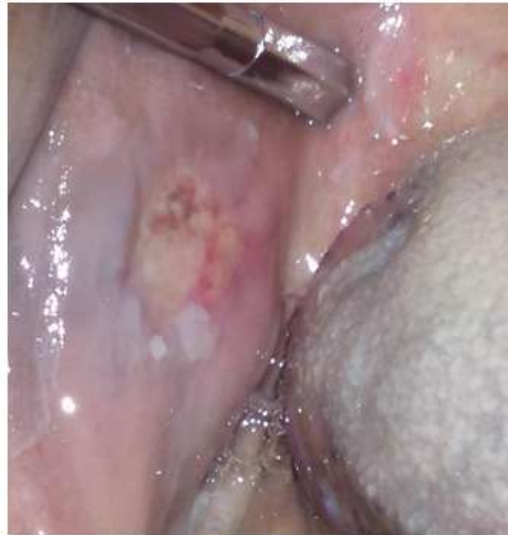**Fig. 1** Diode laser unit



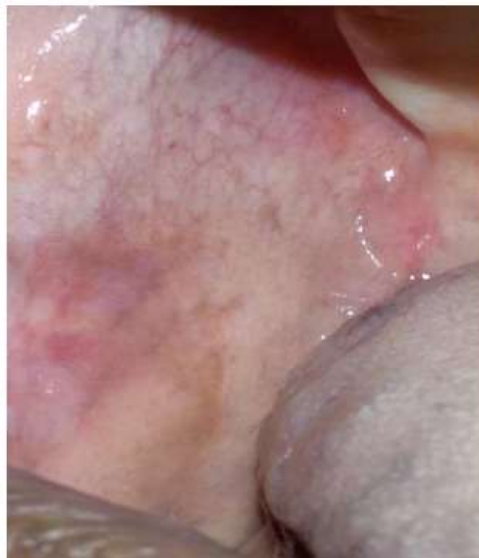**Fig. 2** Leukoplakia of right buccal mucosa



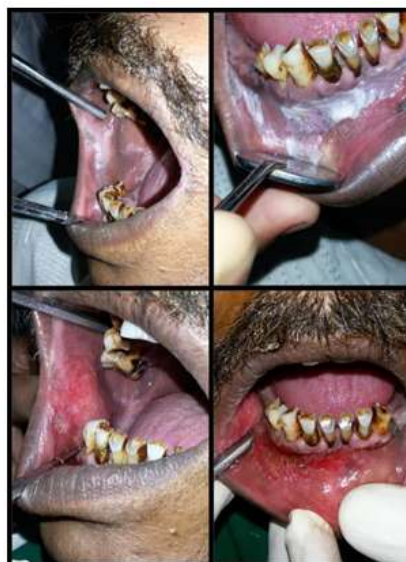**Fig. 3** Immediate postop



**Fig. 4** Very good healing progress on 7<sup>th</sup> postop day



**Fig. 5** Complete healing after 30 days



**Fig. 6** Immediate postop after leukoplakia ablation from buccal and labial mucosa

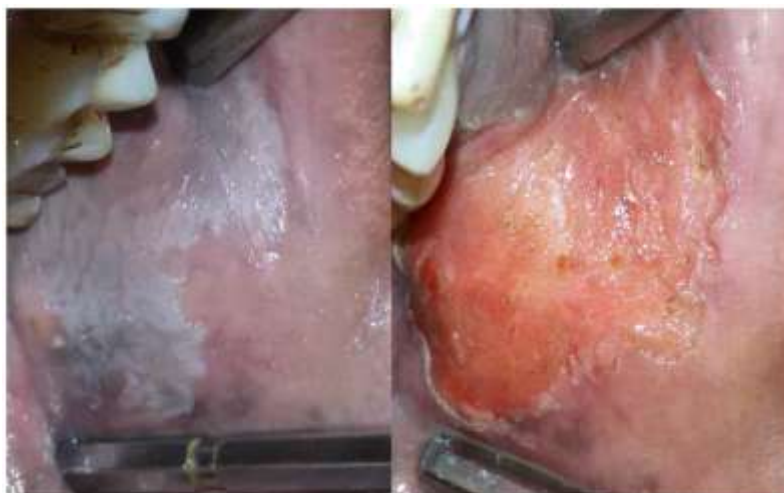


Fig. 7 Immediate postop after leukoplakia ablation from left buccal mucosa

Tables

Table 1. Data Of All The Patients

Serial numbers (Patients)	Age/Sex	Site of lesion	Size of lesion (mm <sup>2</sup> )
1	49/M	Buccal mucosa	23*30
2	42/M	Buccal mucosa	15*20
3	37/M	Labial mucosa	20*25
4	67/M	Buccal mucosa	12*18
5	54/M	Buccal mucosa	27*32
6	44/M	Labial mucosa	10*15
7	58/M	Buccal mucosa	30*35
8	61/F	Buccal mucosa	18*22
9	76/M	Buccal mucosa &	12*17 &
		Labial mucosa	22*28
10	59/M	Buccal mucosa	33*37

Table 2. Postoperative Healing

Serial numbers (Patients)	Healing after 7 days		Healing after 30 days	
	Score	Inference	Score	Inference
1.	3	Good	5	Excellent
2.	3	Good	5	Excellent
3.	4	Very Good	5	Excellent
4.	3	Good	4	Very good
5.	3	Good	5	Excellent
6.	4	Very Good	5	Excellent
7.	3	Good	5	Excellent
8.	4	Very Good	5	Excellent
9.	3	Good	4	Very good
10.	3	Good	5	Excellent

Table 3. Postoperative pain on the basis of VAS (3<sup>rd</sup> postop day)

Sr no. (Patients)	SCORE	INFERENCE
1	0	NO PAIN
2	0	NO PAIN
3	2	MILD PAIN
4	0	NO PAIN
5	2	MILD PAIN
6	2	MILD PAIN
7	0	NO PAIN
8	0	NO PAIN
9	0	NO PAIN
10	2	MILD PAIN